

Assessment of the Effect of Intravitreal Injection of Triamcinolone Acetonide on Intraocular Pressure

Deepti Kumari, S.K Kailwoo, Dinesh Gupta

Abstract

Present study was done to assess the effect of Intravitreal injection of Triamcinolone Acetonide on Intraocular Pressure. This prospective study was conducted on 40 patients attending the Out Patient Department of Upgraded Department of Ophthalmology, Government Medical College & Hospital, Jammu with macular edema associated with diabetic retinopathy (n=30), branch retinal vein occlusion (n=09) and central retinal vein occlusion (n=01), which received 4mg Intravitreal Triamcinolone Acetonide injection. The change in intraocular pressure was followed for all cases at preoperation and at 24 hours, 1 week, 2 week, 1 month, 2 months and at 3 months. Intraocular pressure was raised to mean value of 17.22 (SD 2.92), 18.3 (SD 3.16), 19.17 (SD 3.06), 20.7 (SD 2.64), 21.3 (SD 2.51) mmHg at 24 hours, 1 week, 2 week, 1 month, 2 months from mean baseline intraocular pressure of 16.02 (SD 2.67) mmHg respectively. Maximum mean elevation was seen at 2 months of 21.3 (SD 2.51) mmHg which was highly significant $p < .0001$. It decreased significantly to 19.07 mmHg (SD 2.44) at 3 months of follow up.

Key Words

Intravitreal Triamcinolone Acetonide, Intraocular Pressure, Macular Edema, Diabetic Retinopathy, Retinal Vein Occlusion

Introduction

Intravitreal injection with administration of various pharmacological agents has become a mainstay of treatment in ophthalmology for various retinal diseases as they efficiently deliver the drug to the posterior segment of eye. Various pharmacological agents like Anti-VEGF's, Antifungals, Steroids can be injected intravitreally.

Triamcinolone Acetonide has potent anti-inflammatory, antiangiogenic (1) and antipermeability actions, thereby inhibiting the production of vascular endothelial growth factors (2) and thus helps to maintain blood retinal barrier and facilitates the absorption of exudates. In addition, they inhibit prostaglandins and interleukin synthesis which results in local reduction of inflammatory mediators.

Intravitreal Triamcinolone Acetonide can be used for the treatment of Diabetic Macular Edema, Macular edema associated with Retinal vein occlusion, Proliferative

diabetic retinopathy, Exudative Age Related Macular Degeneration with Choroidal Neovascular Membrane, Posterior Uveitis and Cystoid Macular Edema.

The major side effect of Intravitreal Triamcinolone acetonide is steroid induced elevation of Intraocular pressure (3) which is due to increased resistance to aqueous outflow due to microstructural changes at trabecular meshwork like increase in extracellular proteins, decrease in phagocytic activity of trabecular endothelial cells causing decrease in the breakdown of substances in trabecular meshwork and decrease in prostaglandins that regulate outflow. Changes in the microstructure of trabecular meshwork causes decrease in outflow facility and an increase in intraocular pressure. Corticosteroids also increase the deposition of extracellular matrix in trabecular meshwork leading to

From the Postgraduate Department of Ophthalmology, Govt. Medical College, Jammu -J&K India

Correspondence to : Dr Deepti Kumari, Postgraduate Department of Ophthalmology, Govt. Medical College, Jammu -J&K India

decreased outflow facility. Some found an increased deposition of extracellular material altering the ultrastructure of juxtacanalicular region (4). The reduction in outflow facility may also be due to reduced degradation of substances in trabecular meshwork. Levels of tissue plasminogen activator, stromelysin and metalloproteases were found to be decreased in trabecular meshwork cultures treated with steroids. Furthermore steroids inhibit trabecular meshwork cell arachidonic acid metabolism (5) and reduces phagocytic properties of cells. These cells function to remove the debris deposited in meshwork, reduced functional activity lead to reduced outflow facility. The elevated Intraocular pressure can be controlled temporarily with topical anti glaucoma medications (6). The purpose of this study was to assess the effect of Intravitreal injection of Triamcinolone Acetonide on intraocular pressure.

Material and Material

This prospective study was conducted on 40 patients (40 phakic eyes) attending the Out Patient Department of Upgraded Department of Ophthalmology, Government Medical College & Hospital, Jammu with macular edema associated with diabetic retinopathy (n=30), branch retinal vein occlusion (n=09) and central retinal vein occlusion (n=01), which received 4mg Intravitreal triamcinolone acetonide injection.

An informed consent was taken from all the patients who were included into the study. Patients having history of glaucoma, steroid responders, baseline intraocular pressure >21mmhg were excluded from the study.

All the patients were evaluated preoperatively including best corrected visual acuity, baseline intraocular pressure using non contact tonometer, slit lamp biomicroscopic examination with +90D lens and fundus fluorescein angiography.

The injection was carried out under all aseptic precautions and under topical anesthesia using 0.5% proparacaine. The injection was given in inferotemporal quadrant 3mm from limbus (in aphakics and pseudophakics) and 3.5mm from limbus in phakic patients to ensure the passage of needle through vitreous base. Using a single purposeful continuous maneuver, Triamcinolone acetonide 4mg (0.1ml) was injected transconjunctivally with 30-gauge needle attached to a tuberculin syringe into the eye aiming for mid vitreous cavity. The needle was removed simultaneously with the application of cotton tipped applicator over its entry site to prevent regurgitation of

injected material. Patients were put on topical antibiotic eye drops for a week. The change in intraocular pressure was followed for all cases at 24 hours, 1 week, 2 week, 1 month, 2 month and at 3 months respectively.

Statistical Analysis

Paired t test was used to assess the statistical significance of differences in the Intraocular pressure before and after Intravitreal injection of Triamcinolone acetonide.

Results

Of the 40 patients, 17 were female (42.5%) and 23 were male (57.5%). Intravitreal injection of triamcinolone acetonide was given due to progressive declining of visual acuity due to macular edema associated with diabetic retinopathy (n=30), branch retinal vein occlusion (n=09), central retinal vein occlusion (n=01) as shown in (Fig 1) Intraocular pressure was raised significantly from mean baseline intraocular pressure of 16.02mmhg (SD 2.67) $p < .0001$ to mean maximum value of 21.3mmhg (SD 2.51) $p < .0001$ at 2 months as shown in table 1. The mean increase in intraocular pressure of 5.28mmhg was noted in our study. At 3 months of follow up intraocular pressure decreased significantly to 19.07mmhg (SD 2.44) $p < .0001$ as shown in (Fig -2).

Discussion

Macular edema is the major cause of decreased visual acuity in some of retinal vascular disorders. Capillary leakage due to damaged blood retinal barrier can cause macular edema. Corticosteroids have long been known to tighten up blood vessels resulting in decrease of vessel leakage.

Triamcinolone Acetonide reduces the breakdown of blood retinal barrier after Intravitreal Injection and treat macular edema by means of anti inflammatory and blood retinal barrier stabilizing effects. However, elevation of Intraocular Pressure is a clinically important issue of Intravitreal Triamcinolone Acetonide Injections. So the purpose of our study was to assess the effect of Intravitreal injection of Triamcinolone Acetonide on Intraocular Pressure.

In present study, we found that Intraocular Pressure (mmhg) was raised to mean value of 17.22 (SD 2.921), 18.3 (SD .16), 19.17 (3.06), 20.7 (2.64), 21.3 (SD 2.511) at 24 hours, 1 week, 2 weeks, 1 month and at 2 month respectively. It was raised significantly from mean baseline Intraocular Pressure (mmhg) of 16.025 (SD 2.674) $p < .0001$ to mean maximum value of 21.3 (SD 2.511) $p < .0001$ at 2 months. The mean increase in

Fig.1 Patients Included for Intravitreal Triamcinolone Acetonide

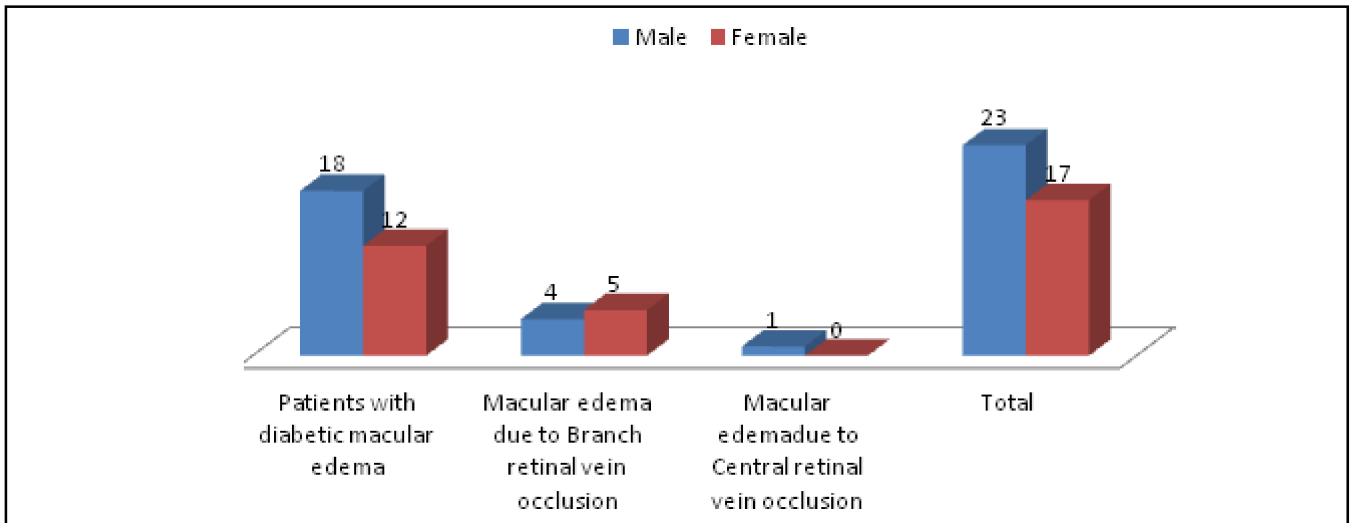
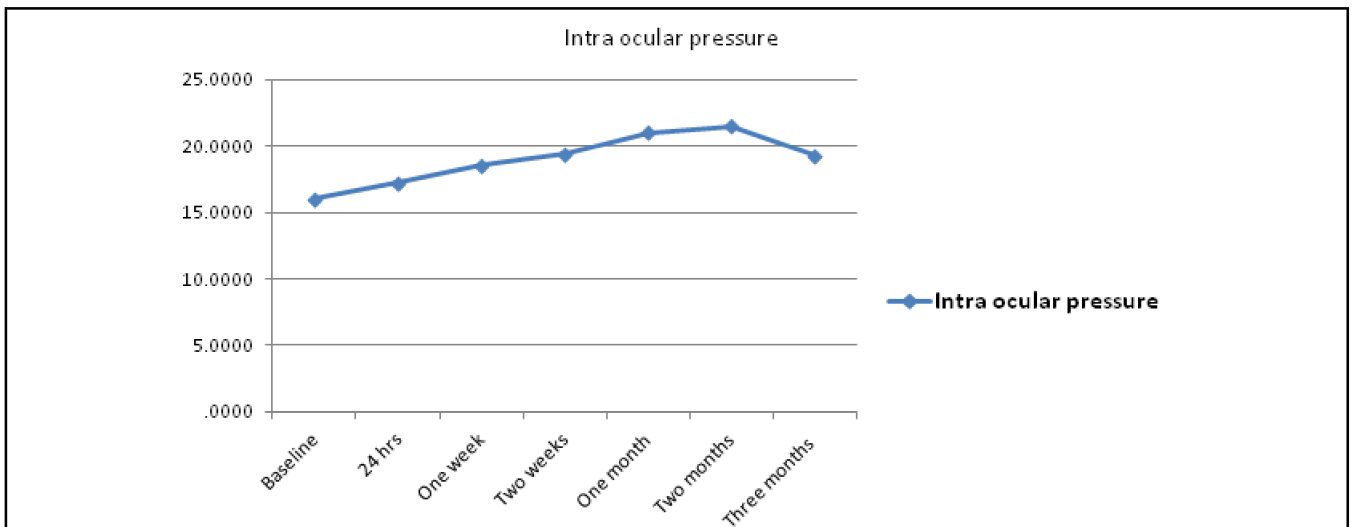


Table 1. Comparison of Intraocular Pressure at Baseline and at 2 Months

Baseline intraocular pressure Mean (SD)	Intraocular pressure at 2 months Mean (SD)	Statistical inference t test
16.02(2.674)	21.3(2.511)	t 14.781 P<.0001 (highly significant)

Fig. 2 Graphical Presentation Showing Change In Intraocular Pressure At Various Follow-ups



Intraocular pressure of 5.28mmhg was noted in our study. Bakri & Beer (7) did their study on 43 consecutive eyes, noted rise of 5mmhg or greater rise of intraocular pressure in 21(27.9%) eyes and 10mmhg or greater in 12(27.9%) eyes. The mean time to reach maximum Intraocular pressure was 6.6 weeks and in our study mean maximum Intraocular pressure was seen at 2 months.. Wang LL *et al* (8) who reported that after giving 4 mg of

Intravitreal Triamcinolone Acetonide in treatment of macular edema, Intraocular Pressure raised significantly from 14.85+-2.55 mmhg preoperatively to mean maximum of 18.80+_6.2 mmhg Intraocular pressure elevation peaked at 2 months which was similar to our study. Smithen LM *et al* (9) noted that in all patients who received 4mg of Intravitreal injection of Triamcinolone Acetonide and followed for 6 months, the

mean pressure increase was 8mmhg and 40.4% experienced pressure elevation of 24mmhg or higher and the pressure elevation occurred at mean of 100.6 days.

In our study Intraocular pressure decreased significantly to 19.07(SD 2.44) $p < .0001$ at 3 months of Intravitreal Injection of Triamcinolone Acetonide. Wang LL *et al* (8) also noted significant decrease in Intraocular pressure to 16.99mmhg at 3 months from maximum elevation of 18.80 mmhg at 2 months. Ozkiris and Erkilic (10) reported a rise in Intraocular Pressure above 21 mmhg in 21% of eyes receiving 8 mg of Intravitreal Triamcinolone Acetonide but in our study we used 4 mg of Triamcinolone acetonide. Triamcinolone Acetonide induced increase in Intraocular Pressure is reversible. The mean elimination half life of Triamcinolone Acetonide is 18.6 days in non vitrectomised patients (11).

Therefore, it remains in vitreous for upto 3 months after delivery in nonvitrectomised eyes and for a much shorter period in vitrectomised eyes.(12)

Singh IP *et al* (13) reported case series of early and rapid increase in Intraocular Pressure following an Intravitreal injection of Triamcinolone Acetonide in three individuals. In all three cases, a significant rise of Intraocular Pressure occurred within one week of Intravitreal injection for macular edema. The significant increase in intraocular pressure was similar to our study.

Wei Y *et al* (14) found that both periocular Triamcinolone Acetonide and Intravitreal Triamcinolone Acetonide injections caused a rise in Intraocular Pressure, which was higher in Intravitreal Triamcinolone Acetonide injected eyes than in periocular Triamcinolone Acetonide injected eyes. The mean rise in Intraocular Pressure was significantly greater in eyes with Intravitreal injection than in those with periocular Triamcinolone Acetonide injections.

Conclusion

Intraocular pressure rises significantly after 4mg injection of Intravitreal Triamcinolone acetonide with maximum peak at two months and decreases significantly at three months. Thus steroid induced ocular hypertension is not a contraindication against the use of Intravitreal Triamcinolone Acetonide as a treatment of macular edema owing to diabetic retinopathy and retinal vein occlusion.

References

1. Wang YS, Friedrichs U, Eichler W, *et al*. Inhibitory effects of Triamcinolone Acetonide on bFGF-induced migration and tube formation in choroidal microvascular endothelial cells. *Graefes Arch Clin Exp Ophthalmol* 2002; 240(1):42-48.
2. Wilson CA, Berkowitz BA, Sato Y, *et al*. Treatment with Intravitreal steroid reduces blood retinal barrier breakdown due to retinal photocoagulation. *Arch Ophthalmol* 1992;110(8):1155-59
3. Wingate RJ, Beaumont PE. Intravitreal Triamcinolone and elevated intraocular pressure. *Aust NZ J Ophthalmol* 1999;27(6):431-32.
4. Wilson K, McCartney MD, Miggans ST, *et al*. Dexamethasone induced ultrastructural changes in cultured human trabecular meshwork cells. *Curr Eyes Res* 1993;12(9):783-93
5. Weinreb RN, Mitchell MD, Polansky JR. Prostaglandin production by human trabecular meshwork cells: in vitro inhibition by dexamethasone. *Invest Ophthalmol Vis Sci* 1983;24(12):1541-45
6. Jonas JB, Degenring RF, Kreissling I, Akkoyun I, Kampeter BA. Intraocular pressure elevated after Intravitreal Triamcinolone Acetonide injection. *Ophthalmology* 2005;112(4): 593-98.
7. Bakri SJ, Beer PM. The effects of Intravitreal Triamcinolone Acetonide on intraocular pressure. *Ophthalmic Surg Lasers Imaging* 2003;34(5):386-90
8. Wang LL, Song HP, Liu B. Changes of intraocular pressure after Intravitreal injection of 4mg Triamcinolone Acetonide in treatment of macular edema. *Int J Ophthalmol* 2008;1(2):139-42
9. Smith LM, Ober MD, Maranan L, Spaide RF. Intravitreal Triamcinolone Acetonide and intraocular pressure. *Am J Ophthalmol* 2004;138(5):740-43
10. Ozkiris A, Erkilic K. Complications of Intravitreal injection of Triamcinolone Acetonide. *Can J Ophthalmol* 2005;40(1):63-68
11. Beer PM, Bakri SJ, Singh RJ, Liu W, Peters GB 3rd, Miller M. Intraocular concentration and pharmacokinetics of Triamcinolone Acetonide after a single Intravitreal injection. *Ophthalmology* 2003;110(4):681-8
12. Conti SM, Kertes PJ. The use of Intravitreal corticosteroid, evidence based and otherwise. *Curr Opin Ophthalmology* 2006; 17 (3):235-44.
13. Singh IP, Ahmed SI, Yeh D, *et al*. Early rapid rise in intraocular pressure after Intravitreal Triamcinolone Acetonide injection. *Am J Ophthalmol* 2004;138(2):286-87
14. Wei Y, Wang HZ, Chen FH, *et al*. Triamcinolone Intravitreal injection and intraocular pressure in macular edema associated with retinal vein occlusion. *Eye Science* 2012;27(4):182-87